

The treatment of type III acromioclavicular dislocations with a modified Cadenat procedure: surgical technique and mid-term results

Simone Cerciello · Thomas Bradley Edwards ·
Brent Joseph Morris · Giuliano Cerciello ·
Gilles Walch

Received: 10 April 2014
© Springer-Verlag Berlin Heidelberg 2014

Abstract

Introduction The treatment of type III acromioclavicular injuries is controversial. Both conservative and surgical approaches have been successful. Aim of the present study was to prospectively evaluate the results of the modified Cadenat procedure in subjects with type III acromioclavicular joint injuries.

Methods Twenty-eight patients with acute type III acromioclavicular joint dislocations (mean age 31 years) were prospectively enrolled in the present study. The delay between the injury and the surgery varied between 4 and 19 days, with an average of 8.3 days. All patients were evaluated both preoperatively and postoperatively with radiographs and clinically with visual analog scale and Constant score. A modified Cadenat procedure was performed in all cases.

Results Twenty-five patients were evaluated at an average follow-up of 72 months. One patient had a re-dislocation 3 years after surgery. At the last follow-up, average visual analog scale score of was 0.96 (range 0–3), while mean constant score was 94.32 (range 90–99) and 92 % of patient were very happy or happy with their functional

result. Radiographs showed complete reduction in 22 patients and loss of reduction in two cases. No major complications were recorded.

Interpretation This is the first clinical report on a modified Cadenat procedure. This operation has a reduced morbidity if compared to other techniques involving autologous grafts. Moreover, it yielded good functional results, with complete pain relief, and full strength recovery at mid-term follow-up. No major loss of reduction or recurrence of instability was observed.

Level of evidence 4, Case series.

Keywords Cadenat procedure · Acromioclavicular dislocation · Acromioclavicular ligament · Coracoclavicular cerclage · Coracoclavicular ligaments · Biologic graft

Introduction

Injuries of acromioclavicular (AC) joint have an incidence of 4 per 100,000 [1–4]; 43.5 % occur in patients in their twenties [5] and they are five times more frequent in males [4]. AC joint injuries account for 9 % of all shoulder girdle injuries, representing the second most common type of dislocation after glenohumeral joint dislocations [3]. Sports account for 25–50 % of all (AC) joint injuries [1, 3, 6]. Rockwood's classification is based on the degree and direction of clavicle displacement and is the most commonly accepted classification [4]. Type I and II AC joint injuries are benign and can be managed conservatively with excellent results [7, 8]. On the contrary, type IV, V and VI AC joint injuries are the consequence of high-energy traumas and often require surgery [9]. There is still controversy concerning the optimal strategy for managing

S. Cerciello · G. Walch
Centre Orthopédique Santy, Lyon, France

S. Cerciello (✉)
Via Riccardo Zandonai 11, 00135 Rome, Italy
e-mail: simone.cerciello@me.com

T. B. Edwards · B. J. Morris
Fondren Orthopaedic Group, Texas Orthopaedic Hospital,
Houston, USA

G. Cerciello
Casa di Cura Villa Betania, Polo Ospedaliero Santo Spirito,
Rome, Italy

type III dislocations [9]. Type III AC injuries have been defined by a superior displacement of the lateral end of the clavicle of one clavicular diameter or 1 cm on the anterior-posterior radiograph [4]. Type III AC joint injuries can be managed conservatively; however, some authors report better results after surgical treatment [10]. Unfortunately, there is no consensus in the literature regarding the best surgical option with more than 60 different reconstruction techniques described for AC joint reconstruction [4]. A recent review reported that open procedures are still very common and stressed the importance of restoring both vertical and horizontal AC joint stability [11]. Most techniques for AC joint reconstruction involve reconstructing the coracoclavicular (CC) ligament. The first article concerning the use of coracoacromial (CA) ligament was the one by Cadenat [12]. He described the detachment of the posterior fascicle off the acromion and its suture to the remnants of the conoid ligament and periosteum of posterior superior aspect of clavicle. The aim of the present study was to evaluate the clinical results of the Cadenat procedure that has been modified by the senior surgeon, in a consecutive group of 28 patients.

Materials and methods

Patients

From 2005 to 2011, 28 patients with acute type III AC joint dislocation (26 males and 2 females) were enrolled in the present study. The diagnosis was confirmed with preoperative radiographs including: anterior-posterior (AP), axillary lateral view of the involved shoulder, and bilateral Zanca views [13]. Additional CT scan was available in 16 cases (Fig. 1). Preoperatively, all patients had shoulder pain, deformity, and weakness that interfered with daily activities. Range of motion was variable and limited secondary to pain. Mean age at the time of surgery was 31 years (range 19–51). The dominant arm was affected in 18 cases. Ten patients were injured while participating in sports, while 18 were involved in motor vehicle accidents. However, all patients practiced sports at least at the recreational level before initial injury. The sports practiced included swimming in six cases, volleyball in four, basketball in three, soccer in eight, weight lifting in three, and jogging in four. All patients were highly motivated and, after comprehensive explanation of the possible treatment options, elected for surgical treatment. The delay between the time of injury and time to surgery varied between 4 and 19 days, with an average of 8.3 days. Patients' pain scores were evaluated with a 10-point visual analog scale (VAS) (with 0 representing no pain and 10 representing severe pain). Shoulder function was assessed with the Constant

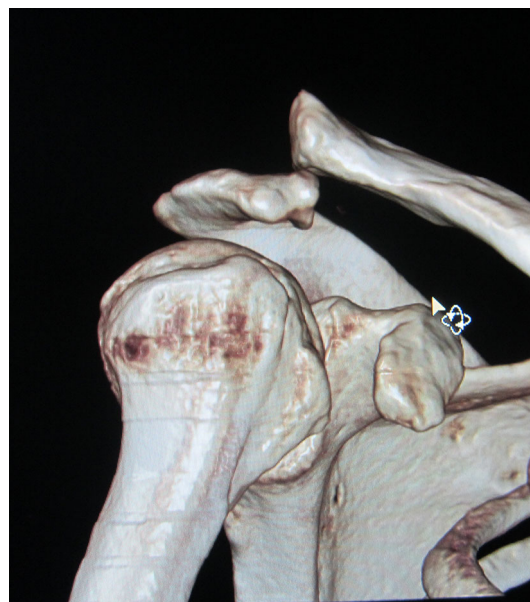

Fig. 1 CT scan allowed precise visualization of displacement

score [14]. It is a four part scoring system ranging from 1 to 100, with 100 being highest. The four subsections: pain, limitations in daily activities, range of movement, and strength were scored as well. The patients were followed-up postoperatively at 1, 3, 6, and 12 months, and then yearly by a surgeon who did not attend the operation. Average time for return to sport was recorded. Assessment of AC joint reduction, using comparative Zanca views was performed at each follow-up. At the last follow-up, subjective results and the level of satisfaction in relation to the ability to carry out activities of daily living were evaluated with the question: how would you rate your satisfaction after surgery—do you feel very satisfied, satisfied or not satisfied?

All the methods described in this article were approved by the local ethics committee (Health Director of the Villa Betania Hospital in Rome) and all patients gave informed consent to be included in the study.

Statistical analysis

Statistical analysis of the preoperative and postoperative values was performed using the Wilcoxon signed-rank test: XLSTAT 2009 (v. 3.01, AddinsoftTM software) setting the alpha value at 0.05.

Surgical technique

Patients are operated following the principles of the original Cadenat procedure [12]. The key points of the original technique include suturing the CA ligament to the

remnants of the conoid ligament and preservation of the lateral end of the clavicle. The original technique has been modified by the senior surgeon (GC) adding a coracoclavicular cerclage, suturing the remnants of the CC ligaments, and providing temporary fixation of the AC joint with two Kirschner wires. Patients lie in beach chair position with the arm at side to increase CC space secondary to the weight of the arm hanging free. The skin incision is vertical just lateral to the tip of the coracoid process extending from the posterior margin of the clavicle to the coracoid. Usually the trapezius muscle is intact, whereas deltoid is sometimes damaged at its clavicular insertion. The AC joint is noted to be in a dislocated position and easily detectable with its capsule interrupted. Deltoid fibers are detached from the clavicle up to the level of the coracoid process. Conoid and trapezoid remnants are recognized and if possible they are sutured at the end of the procedure. The CA ligament is identified at the level of its insertion on lateral aspect of the coracoid. The anterior aspect of the ligament is then followed-up to its acromial insertion. Careful sharp dissection of the CA ligament of the acromial side usually allows for a graft of 3–4 cm. The graft is mobilized and all adhesions are removed. The graft is then tubularized with two #2 non-absorbable sutures (Fig. 2). At this time the coracoid process is prepared; the proximal 1 cm of the pectoralis minor is detached from its insertion as well as the coracohumeral ligament (with the arm in external rotation). Finally, the deep surface of the coracoid process is released to pass a loop of absorbable shuttle suture from medial to lateral. A portion of the trapezius muscle is detached from the clavicle at the level of coracoid projection to create a small hole. The remnants of the conoid and trapezoid ligaments are evaluated to determine their integrity. Two #2 absorbable sutures are passed underneath the coracoid from medial to lateral. The two free ends emerging from the medial aspect of the coracoid are passed posteriorly to the clavicle into the hole created in the trapezius. With a bur, small hole is performed on the clavicle in correspondence of the stump of the CC ligaments (Fig. 3). The diameter of the cylindrical hole is around 5×8 mm (with the major extension on frontal plane of the clavicle) and must be sufficient to sustain the graft. However, at this level the clavicle is flat and large and is only slightly weakened by the tunnel (which is 5 mm in the sagittal plane). The clavicle is now mobilized to determine if the length of the ligament will fit or not. If not, the anterior part of the ligament can be securely released from the coracoid process. The preliminary part of harvesting and preparation is now completed. The AC joint is reduced and fixed with two Kirschner wires. The two wires are inserted through a small skin incision at the lateral margin of the acromion across the joint. The two K wires free ends are then cut, flexed at

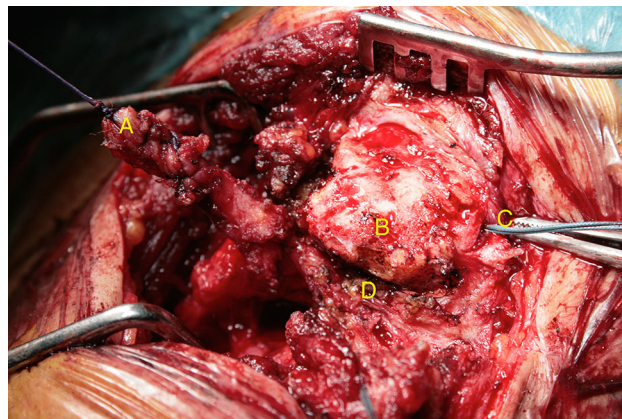


Fig. 2 Once the coracoacromial ligament (A) has been completely released, it is tubularized with two #2 non-absorbable sutures. Coracoclavicular cerclage (C) is passed underneath the clavicle (B) and medial to the AC joint (D)

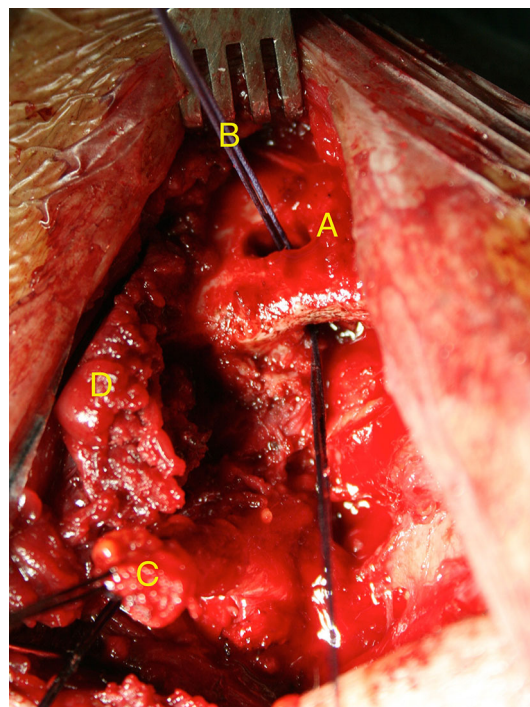


Fig. 3 The clavicular tunnel (A) is performed at the level of CC ligaments stump where the risk of weakening the clavicle is lower. AC ligament is passed through the hole with a shuttle suture (B). The medial part of the deltoid muscle (D) has been partially detached to improve visualization and must be carefully reinserted at the end of the operation

90° and secured under the skin. The two sutures of the tubularized graft are passed through the clavicular tunnel. The posterior suture is passed around the clavicle and then tied to the anterior one. The remnants of the CC ligaments are sutured to the graft. The two sutures of the CC cerclage

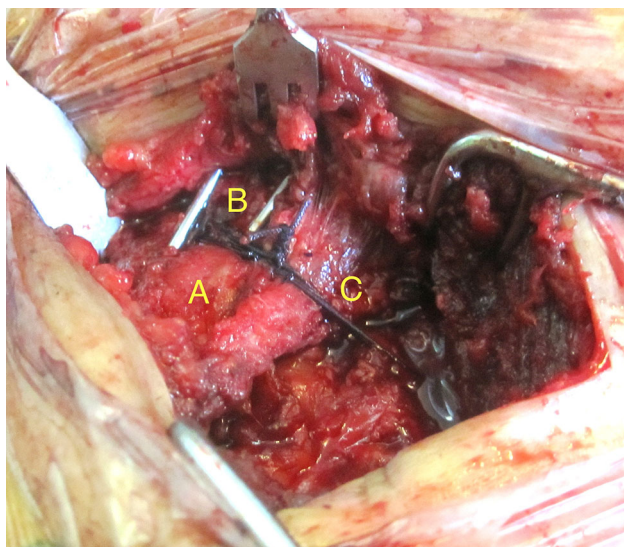


Fig. 4 The coracoclavicular cerclage (C) acts as additional fixation, helping the control of residual anterior–posterior instability. The two K wires (B) are inserted through the acromion (A) into the clavicle to enhance initial stability

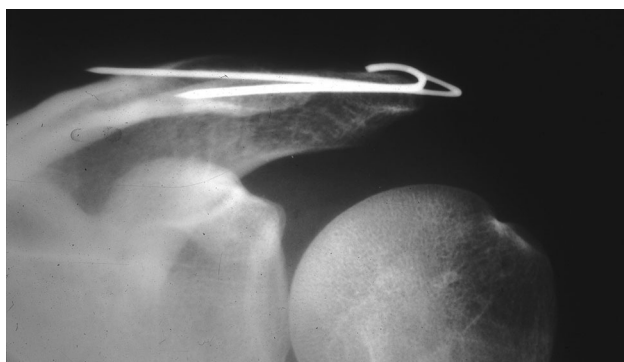


Fig. 5 Postoperative X-ray control showing perfect reduction. The K wires are removed at 6 weeks

are tied independently (Fig. 4). The anatomy of the CC ligament is then restored, while the Kirschner wires and the CC cerclages increase stability. Local pressure necrosis on the cortex of the clavicle is minimized, by using only absorbable sutures, thus reducing the risk of osteolysis. Trapezius and deltoid muscle and fascia are then repaired with direct reinsertion to bone. Postoperative X-ray is performed the day after the operation (Fig. 5). The arm remains in a sling for 6 weeks. Range of motion of the elbow and wrist is encouraged. Shoulder passive motion begins at 4 weeks. At 6 weeks, the Kirschner wires are removed in operating room. Water therapy is then allowed beginning with active motion and continuing with breast-stroke at the beginning of the second month. Strengthening exercises are allowed from the fourth month.

Results

3 patients were lost to follow-up, and 25 patients were reviewed with an average follow-up of 72 months (range 24–96 months). One patient had a re-dislocation after a high-energy trauma due to a motorbike accident 3 years after surgery. Before the accident he had no pain, the Constant score was 97.0 and he had complete reduction at X-ray control. Although he was considered as a failure, his outcome was included in the present series. Average VAS improved from 6.40 ± 0.91 (range 5–8) to 0.96 ± 1.09 (range 0–3), $p < 0.0001$. Average constant score improved from 62.28 ± 2.90 (range 56–67) to 94.32 ± 2.91 (range 90–99), $p < 0.0001$. Average score on the pain section improved from 8.2 ± 1.32 to 13.8 ± 2.17 ($p < 0.0001$), average score on the activities of daily living section from 10.88 ± 1.56 to 18.24 ± 1.33 ($p < 0.0001$), average score on the range-of-motion section improved from 25.32 ± 1.10 to 39.28 ± 0.97 ($p < 0.0001$), while average score on the strength section from 17.88 ± 1.01 to 23.20 ± 1.75 ($p < 0.0001$). The mean time to return to sport was 24 weeks (range 21–26). At the last follow-up, radiographs showed complete reduction in 22 patients and partial loss of reduction (less than half of the clavicle width) in two cases. Moreover, no evidence of AC degenerative changes was detectable at this time. One superficial pin tract infection required hardware removal and antibiotic therapy. No major complications were recorded. Subjective results at the last follow-up were: 16 patients were very satisfied (64 %), 7 were satisfied (28 %) and 2 were not satisfied with their functional results (8 %). Nineteen patients (76 %) returned to the same type of sport at the same level. Two (8 %) of the 25 patients reduced the level of sport or the type of sport for reasons unrelated to the surgery. Four of the 25 patients (16 %, all recreational) reduced the level of sport or changed it as they thought their shoulder was not adequate to return to their pre-injury activity levels.

Discussion

Stability at the AC joint is the consequence of static and dynamic stabilizers. The AC joint capsule and the AC ligaments (anterior, posterior, inferior and superior) play a fundamental role in stabilizing the clavicle in a horizontal plane (anterior to posterior direction) [2]. On the contrary, the CC ligaments (conoid and trapezoid) are the primary restraints to vertical (superior to inferior) translation at the AC joint [15]. However, the CC ligaments also have important influence in the horizontal plane [15]. Once anatomical damage has occurred as a consequence of direct or indirect trauma, the classification of the injury is crucial

to adopt the appropriate treatment. Rockwood proposed a 6-stage classification according to the direction and extent of clavicular displacement as a consequence of anatomic damage [4]. Type III AC joint injuries have been defined by a superior displacement of the lateral clavicle of 1 cm. They represent a challenging issue in terms of treatment and surgical approach. In fact both AC and CC ligaments are torn, but the deltoid and trapezius fascia are intact. The distal clavicle may be prominent enough to tent the skin and can be unstable in both the vertical and horizontal planes [5]. Literature shows no difference in strength at 2-year follow-up between surgery and conservative treatment [16]. Moreover, in a prospective study, rates of persistent symptoms were similar between the operative (2/25, 8 %) and non-operative (3/29, 10 %) groups [17]. These data were confirmed by the meta-analysis of Smith, who showed better cosmetic outcomes, but no difference in terms of strength, pain and throwing ability [18]. However, in young and motivated patients, surgery can be advisable [19]. Most of surgical techniques aim to restore the function of CC ligaments through biologic graft. Although Weaver and Dunn were considered to be the first to introduce the use of the CA ligament to reconstruct the CC ligaments in 1972 [20], the first article concerning the use of CA ligament was the one by Cadenat [12], followed by the one of Nevaizer in 1952 [21]. Cadenat in his original article, described anterior and posterior fascicles of the CA ligament, detached the posterior fascicle off the acromion and sutured it to remnants of the conoid ligament and periosteum of posterior superior aspect of clavicle. The lateral end of clavicle was retained and no adjunct fixation was used [12]. With the coracoid left intact, the possibility of its use for revision fixation by one of a number of described techniques is not precluded. To our knowledge, only three articles reporting the results of the Cadenat procedure are available in the literature [22–24]; however, they report different variations to the original technique. The modified Cadenat procedure described in the present study has some crucial aspects that must be stressed: timing, distal clavicle retention, additional temporary fixation, and clavicle anterior–posterior AC joint stability. The procedure has been performed in acute cases within 3 weeks of the initial injury. However, the dividing line between acute and chronic injuries is controversial since it has been defined as 2 weeks [25], 3 weeks [26], and 4 weeks [27]. Furthermore, in this technique the biologic effect of the transferred CA ligament is increased with the suture of the CC ligaments. Distal clavicle retention in young and active patients is advantageous as demonstrated by several authors who have shown the importance of the AC ligaments and capsule to the stability of lateral end of clavicle during both small and large amounts of loading [2, 28–30]. Temporary fixation was achieved with two

Kirschner wires to maintain the reduction and then protect the healing of the transferred ligament. Surgical techniques that involve CA ligament transposition have not ensured appropriate early fixation to restore the stability of the intact joint before ligament healing [31]. In the present study, temporary fixation was achieved with two Kirschner wires. Some authors showed that posttraumatic arthritis develops more frequently by using transarticular fixation techniques [32, 33], while others stated that temporary fixation with Kirschner wires was inadequate due to migration of wires or failure of fixation requiring removal or revision [34]. In the present series, no complications have been associated with K wires (except one case of infection), and at the last follow-up no evidence of AC degenerative changes was detectable at X-ray analysis. Another controversial aspect of the techniques involving the CA ligament transfer is the poor control of anterior–posterior stability. This issue is crucial since it is responsible for residual pain and degenerative changes in AC joint. For this reason, some authors suggest an additional AC joint capsular repair to provide additional stability [35]. The described CC cerclage may play additional role to the stability in the anterior–posterior direction. The reported series confirms the efficacy of the modified Cadenat procedure in achieving good functional results and preventing loss of correction or recurrence of instability. The results are hardly comparable to those reported by Takase [24] who performed his modified Cadenat procedure in patients with type V dislocations and evaluated the outcomes with the UCLA scale. The outcomes of the present study are comparable with the latest series in the literature reporting the outcomes of arthroscopic [36], arthroscopically assisted [37], or open techniques [38], confirming the efficacy of the procedure. Nevertheless this study has several limitations. First of all, the lack of a control group prevents from the precise efficacy of the modifications of the original technique. Moreover, the length of the FU does not allow for definitive conclusion concerning the onset of degenerative changes to the AC joint.

Conclusions

The modified Cadenat procedure represents a good option in the treatment of type III AC dislocations. The possibility of clavicle fixation with a biologic graft as well as the low harvest morbidity is advantageous. Moreover, the modifications to the original technique, such as temporary fixation of AC joint and CC cerclage are advantageous since they may enhance the initial strength of the construct and improve the anterior–posterior stability of the joint. The outcomes are successful in terms of pain relief, function and strength. No major loss of reduction or recurrence of

neither instability, nor adverse effect related to the temporary fixation with Kirschner wires were observed.

References

- Costic RS, Labriola JE, Rodosky MW, Debski RE (2004) Biomechanical rationale for development of anatomical reconstructions of coracoclavicular ligaments after complete acromioclavicular joint dislocations. *Am J Sports Med* 32(8):1929–1936
- Fukuda K, Craig EV, An KN, Cofield RH, Chao EY (1986) Biomechanical study of the ligamentous system of the acromioclavicular joint. *J Bone Joint Surg Am* 68:434–440
- Lemos MJ (1998) The evaluation and treatment of the injured acromioclavicular joint in athletes. *Am J Sports Med* 26(1):137–144
- Rockwood CA Jr, Williams GR, Young DC (1996) Injuries to the acromioclavicular joint. In: Rockwood CA Jr, Green DP, Buchholz RW (eds) *Rockwood and Green's fractures in adults*, 4th edn. Lippincott-Raven, Philadelphia, p 1341–1407
- Bontempo NA, Mazzocca AD (2010) Biomechanics and treatment of acromioclavicular and sternoclavicular joint injuries. *Br J Sports Med* 44:361–369
- Dias JJ, Gregg PJ (1991) Acromioclavicular joint injuries in sport recommendations for treatment. *Sports Med* 11(2):125–132
- Hootman JM (2004) Acromioclavicular dislocation: conservative or surgical therapy. *J Athl Train* 39:10–11
- Rolf O, Hann von Weyhern A, Ewers A, Boehm TD, Gohlke F (2008) Acromioclavicular dislocation Rockwood III–V: results of early versus delayed surgical treatment. *Arch Orthop Trauma Surg* 128:1153–1157
- Bradley JP, Elkousy H (2003) Decision making: operative versus nonoperative treatment of acromioclavicular joint injuries. *Clinics Sports Med* 22:277–290
- Gstettner C, Tauber M, Hitzl W, Resch H (2008) Rockwood type III acromioclavicular dislocation: surgical versus conservative treatment. *J Shoulder Elbow Surg* 17:220–225
- Tauber M (2013) Management of acute acromioclavicular joint dislocations: current concepts. *Arch Orthop Trauma Surg* 133(7):985–995. doi:10.1007/s00402-013-1748-z
- Cadenat FM (1913) Traitment des luxations et fractures externes de la clavicle. Thèse médecine. Paris n°195
- Zanca P (1971) Shoulder pain: involvement of the acromioclavicular joint. Analysis of 1,000 cases. *Am J Roentgenol Radium Ther Nucl Med* 112:493–506
- Constant CR, Murley AH (1987) A clinical method of functional assessment of the shoulder. *Clin Orthop Relat Res* 214:160–164
- Mazzocca AD, Arciero RA, Bicos J (2007) Evaluation and treatment of acromioclavicular joint injuries. *Am J Sports Med* 35:316–329
- Tibone J, Sellers R, Tonino P (1992) Strength testing after third-degree acromioclavicular dislocations. *Am J Sports Med* 20:328–331
- Larsen E, Hede A (1987) Treatment of acute acromioclavicular dislocation. Three different methods of treatment prospectively studied. *Acta Orthop Belg* 53:480–484
- Smith TO, Chester R, Pearse EO, Hing CB (2011) Operative versus non-operative management following Rockwood grade III acromioclavicular separation: a meta-analysis of the current evidence base. *J Orthop Traumatol* 12:19–27
- Phillips AM, Smart C, Groom AF (1998) Acromioclavicular dislocation. Conservative or surgical therapy. *Clin Orthop Relat Res* 353:10–17
- Weaver JK, Dunn HK (1972) Treatment of acromioclavicular injuries, especially complete acromioclavicular separation. *J Bone Joint Surg Am* 5:1187–1194
- Neviaser J (1952) Acromioclavicular dislocation treated by transfer of the coracoacromial ligament. *Arch Surg* 64:292–297
- Marcone L (1985) Contribution à l'étude du traitement chirurgical des disjonctions acromio-claviculaires anciennes. A propos du 23 cas traités par la méthode de Cadenat modifiée. Thèse médecine. Grenoble n°110
- Saragaglia D, Julliard R, Marcone L, Butel J (1987) L'intervention de Cadenat dans le traitement des disjonctions acromio-claviculaires anciennes et équivalents. *Rev Chir Orthop* 73(Suppl II):187–190
- Takase K, Shinmura K, Kono R, Kumakura T (2011) Therapeutic results of the modified Cadenat procedure for acromioclavicular joint separations compared with the modified Dewar procedure. *West Indian Med J* 60(3):303–307
- Zaricznyj B (1976) Late reconstruction of the ligaments following acromioclavicular separation. *J Bone Joint Surg Am* 58:792–795
- De Palma AF (1963) Surgical anatomy of acromioclavicular and sternoclavicular joints. *Surg Clin North Am* 43:1541–1550
- Berson BL, Gilbert MS, Green S (1978) Acromioclavicular dislocations: treatment by transfer of the conjoined tendon and distal end of the coracoid process to the clavicle. *Clin Orthop Relat Res* 3:157–164
- Bargren JH, Erlanger S, Dick HM (1978) Biomechanics and comparison of two operative methods of treatment of complete acromioclavicular separation. *Clin Orthop Relat Res*:267–272
- Cox JS (1992) Current method of treatment of acromioclavicular joint dislocations. *Orthopedics* 15:1041–1044
- Urist M (1946) Complete dislocation of the acromioclavicular joint: the nature of the traumatic lesion and effective methods of treatment with an analysis of 41 cases. *J Bone Joint Surg Am* 28:813–837
- Jari R, Costic R, Rodosky M, Debski RE (2004) Biomechanical function of surgical procedures for acromioclavicular joint dislocation. *Arthroscopy* 20:237–245
- Post M (1985) Current concepts in the diagnosis and management of acromioclavicular dislocations. *Clin Orthop* 200:234–247
- Taft T, Wilson F, Oglesby J (1987) Dislocation of the acromioclavicular joint. An end-result study. *J Bone Joint Surg Am* 69:1045–1051
- Brunelli G, Brunelli F (1988) The treatment of acromioclavicular dislocation by transfer of the short head of biceps. *Int Orthop* 12:105–108
- Luis GE, Yong CK, Singh DA, Sengupta S, Choon DS (2007) Acromioclavicular joint dislocation: a comparative biomechanical study of the palmaris-longus tendon graft reconstruction with other augmentative methods in cadaveric models. *J Orthop Surg Res* 27(2):22
- Liu X, Huangfu X, Zhao J (2013) Arthroscopic treatment of acute acromioclavicular joint dislocation by coracoclavicular ligament augmentation. *Knee Surg Sports Traumatol Arthrosc* 10. [Epub ahead of print] doi:10.1007/s00167-013-2800-9
- Venjakob AJ, Salzmann GM, Gabel F, Buchmann S, Walz L, Spang JT, Vogt S, Imhoff AB (2013) Arthroscopically assisted 2-bundle anatomic reduction of acute acromioclavicular joint separations: 58-month findings. *Am J Sports Med* 41(3):615–621. doi:10.1177/0363546512473438
- Läderrmann A, Grosclaude M, Lübbecke A, Christofilopoulos P, Stern R, Rod T, Hoffmeyer P (2013) Acromioclavicular and coracoclavicular cerclage reconstruction for acute acromioclavicular joint dislocations. *J Shoulder Elbow Surg* 20(3):401–408. doi:10.1016/j.jse.2010.08.007