

# No relationship between critical shoulder angle and glenoid erosion after shoulder hemiarthroplasty: a comparative radiographic study

S. Cerciello<sup>1,2,10</sup> · B. J. Morris<sup>3</sup> · E. Visonà<sup>4</sup> · K. Corona<sup>5</sup> · T. B. Edwards<sup>6</sup> · N. Maffulli<sup>7,8</sup> · G. Walch<sup>9</sup>

Received: 27 October 2016  
© Springer-Verlag Berlin Heidelberg 2017

## Abstract

**Introduction** Symptomatic glenoid erosion is one of the most common causes of functional impairment after shoulder hemiarthroplasty. A decrease in the critical shoulder angle (CSA) has been associated with the development of shoulder arthritis. The inter-observer reliability of the CSA and the relationship between CSA and symptomatic glenoid erosion after shoulder hemiarthroplasty were investigated.

**Materials and methods** Twenty-eight patients with symptomatic glenoid erosion after anatomic hemiarthroplasty were compared to a control group of 30 patients with no signs of symptomatic glenoid erosion. The CSA was

measured by two blinded shoulder surgeons at a mean follow-up of 105.2 and 54.7 months, respectively. The inter-observer reliability was calculated.

**Results** The mean CSA in the control group in neutral, internal, and external rotations was 34°, 33°, and 33°, respectively. The corresponding values in the study group were 33°, 33°, and 33° ( $P < 0.01$ ). The interclass correlation coefficient between the two examiners was 0.917 ( $P < 0.01$ ), 0.924 ( $P < 0.01$ ), and 0.948 ( $P < 0.01$ ), respectively. The Mann–Whitney test between the control group and the study group were, respectively, 0.907, 0.932, and 0.602.

**Conclusion** There were no significant differences of CSA values between the two groups. Good inter-observer reliability was found for the CSA method.

✉ S. Cerciello  
simone.cerciello@me.com

<sup>1</sup> Casa di cura Villa Betania, via Piccolomini 27, Rome, Italy

<sup>2</sup> Marrelli Hospital, via Gioacchino da Fiore 0962, Crotona, Italy

<sup>3</sup> Shoulder and Elbow Surgeon Lexington Clinic Orthopedics, Sports Medicine Center, The Shoulder Center of Kentucky, Lexington, USA

<sup>4</sup> Ospedali Riuniti Padova Sud, ULSS 17, Schiavonia, PD, Italy

<sup>5</sup> Università degli Studi del Molise, Campobasso, Italy

<sup>6</sup> Fondren Orthopaedic Group, Texas Orthopaedic Hospital, Houston, USA

<sup>7</sup> Department of Musculoskeletal Disorders, University of Salerno School of Medicine and Surgery, Salerno, Italy

<sup>8</sup> Centre for Sports and Exercise Medicine, Queen Mary University of London, Barts and The London School of Medicine and Dentistry, London, UK

<sup>9</sup> Centre Orthopédique Santy, Lyon, France

<sup>10</sup> Via R. Zandonai 11, 00135 Rome, Italy

**Keywords** Critical shoulder angle · Shoulder hemiarthroplasty · Glenoid erosion · Glenoid arthritis

## Introduction

Neer published the first report on shoulder hemiarthroplasty in 1970 in patients with four-part proximal humerus fractures [1]. The indications for hemiarthroplasty expanded to include osteoarthritis (OA) [2], osteonecrosis [3], rheumatoid arthritis [4], rotator cuff tear arthropathy [5], and fracture sequelae [6]. Optimal results after hemiarthroplasty require an intact rotator cuff and minimal or no glenoid wear. However, glenoid erosion can still develop over time causing pain, patient dissatisfaction, and the need for revision surgery [7–11]. Symptomatic glenoid erosion is an early cause of clinical deterioration, with an incidence of 6–72% [12, 13]. The association between the anatomic factors and the onset of glenohumeral OA has been investigated. Moor et al. recently

introduced the concept of the critical shoulder angle (CSA) [14, 15]. The authors found significantly smaller angle values (CSA of  $<30^\circ$ ) in patients with glenohumeral arthritis when compared to asymptomatic controls. The first aim of the present study was to compare the CSA values in a population of patients with symptomatic glenoid erosion requiring revision surgery after shoulder hemiarthroplasty to a control group with no symptomatic glenoid erosion after hemiarthroplasty. The second aim was to measure the inter-observer reliability of the CSA in patients following hemiarthroplasty. We hypothesized that patients with symptomatic glenoid erosion would have lower CSA values than the control group. We also hypothesized that the CSA measurements would demonstrate good inter-observer reliability.

## Materials and methods

For this type of study, our ethics committee informed that formal consent was not required.

Twenty-eight patients from a single surgeon (GW) consecutive series with symptomatic contained glenoid erosion requiring revision surgery after primary anatomic hemiarthroplasty were enrolled as a study group. The diagnosis of glenoiditis was set at FU according to the clinical symptoms (painful restrictions of the arch of motion with negative cuff tests), negative blood samples, and imaging showing progressive narrowing of joint line. The X-ray evaluation was carried out according to the methodology described by Parsons et al. [7]. Patients had true AP view to avoid any overlap between the humeral head and the glenoid. Serial X-rays revealed progressive reduction of the cartilage width confirming the diagnosis of progressive glenoid erosion. However, the indication for revision was mainly given on clinical basis. In the same way, a group of 30 patients randomly selected from the same consecutive series were enrolled as a control group. They all had the same anatomic hemiarthroplasty but did not show any clinical or imaging signs of glenoid erosion. The indications for surgery in the symptomatic group included glenohumeral OA (13 patients), proximal humeral fractures (14 patients), and osteonecrosis of the humeral head (1 patient). Similarly, the indications for surgery in the control group included osteoarthritis (13 patients), proximal humeral fractures (13 patients), and osteonecrosis of the humeral head (4 patients). Subjects with previous operations on the affected shoulder were excluded from the study. The study population consisted of 12 male and 16 female patients with a mean age at the time of surgery of 58.9 years (range 32–76). The dominant side was involved in 19 cases. The control group consisted of 9 male and 21 female patients with a mean age at the time of surgery of 63.9 years (range 45–81). The dominant side was involved in 18 cases. All patients were evaluated

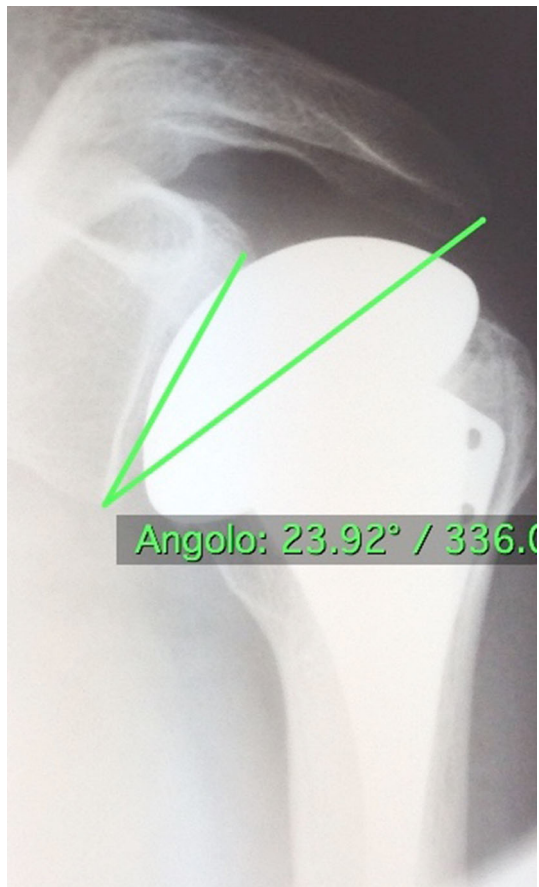
with plain antero-posterior radiographs of the glenohumeral joint with the arm in neutral position, internal rotation, and external rotation. Moor et al. demonstrated that small degrees of scapular rotation did not affect the CSA [12, 13]. In the present investigation, three different arm rotations were available, with a fixed scapular position. Any overlap between the prosthetic head in the different rotations and the glenoid fossa influencing the measure was recorded. The CSA was calculated on the preoperative radiographs performed just before revision surgery in the study group (53.7 months after the primary procedure) and at the last available follow-up (99.7 months after primary procedure) in the control group.

Each antero-posterior radiograph was performed ensuring visualization of the joint space with minimal overlap between the anterior and posterior joint surfaces [12, 13]. The CSA was calculated according to the method described by Moor et al. [14] with the OsiriX software [16]. The angle was drawn between a line connecting the inferior and the superior poles of the glenoid fossa and another line connecting the inferior apex of the glenoid with the most infero-lateral aspect of the acromion (Fig. 1). A decreased CSA is a result of reduced acromial coverage and inclination of the glenoid, theoretically causing an increase in compressive loads on the articular cartilage [14]. The CSA values were calculated in true glenoid antero-posterior views with the arm in neutral rotation,  $20^\circ$  of external rotation and  $20^\circ$  of internal rotation. The reproducibility with different arm positions was calculated. Two blinded shoulder surgeons completed the CSA measurements to assess the inter-observer reliability of the method.

Statistical analysis was performed using SPSS 22 for Windows. A sample size of 28 patients in each group was required for a statistical power of 80% at a type I error level of 0.05. Effect sizes calculated with G Power 3.1 calculator was 1.8. Exploratory data analysis was performed to establish whether the data were normally distributed and whether any significant differences in distribution existed across the groups using Q–Q plots and the Kolmogorov–Smirnov test. Since the data were considered non-parametric, post hoc non-parametric tests were used to assess significant differences between the values. The reproducibility of the method was assessed with the interclass correlation coefficient (ICC) and comparison between the groups was performed with the Mann–Whitney test. The significance level was set at  $P < 0.05$ .

## Results

The radiographs of the 30 patients of the control group were evaluated at a mean follow-up of 105.2 months (range 12–208). None of the patients reported



**Fig. 1** CSA was calculated according to the method described by Moor

glenohumeral joint pain, and no patient had radiographic evidence of glenoid erosion. The CSA values are summarized in Table 1. For the first examiner, the mean CSA value for the AP view with the arm in neutral position was  $34^\circ$  (range 18–49), for the view with the arm in internal rotation, it was  $33^\circ$  (range 19–48), and for the view with the arm in external rotation, the mean CSA value was  $33^\circ$  (range 19–48). The corresponding values for the second examiner were  $32^\circ$  (range 19–49),  $33^\circ$  (range 18–45), and  $33^\circ$  (range 18–47), respectively. In the study group, all 28 patients were revised for symptoms and radiographic signs

**Table 1** Mean values for the CSA in the two groups for the two surgeons and the interclass correlation coefficient

	CSA neutral rotation	CSA internal rotation	CSA external rotation
Control group observer 1	$34^\circ \pm 7.71$	$33^\circ \pm 7.40$	$33^\circ \pm 7.42$
Study group observer 1	$33^\circ \pm 4.28$	$33^\circ \pm 4.48$	$33^\circ \pm 4.57$
Control group observer 2	$32^\circ \pm 7.53$	$33^\circ \pm 7.13$	$33^\circ \pm 7.75$
Study group observer 2	$32 \pm 3.66$	$31 \pm 4.55$	$32^\circ \pm 4.48$
Interclass correlation coefficient	0.917	0.924	0.948
<i>P</i> value	<0.01	<0.01	<0.01

CSA critical shoulder angle

of glenoid erosion at a mean follow-up of 53.7 months (range 12–189). The radiographs performed before revision surgery were measured. The mean CSA value for the AP view with the arm in neutral position was  $33^\circ$  (range 27–43), for the view with the arm in internal rotation, it was  $33^\circ$  (range 25–43), and for the view with the arm in external rotation, it was  $33^\circ$  (range 24–42). The measurements were performed using the same technique by a second observer. The corresponding angles for the second examiner were  $32^\circ$  (range 25–41),  $31^\circ$  (range 20–40), and  $32^\circ$  (range 24–42), respectively. The Kolmogorov–Smirnov test showed that all groups had similar distribution. The same similar values emerged when the different aetiologies (primary osteoarthritis, head necrosis, and fracture) in the two groups were compared.

The interclass coefficient is summarized in Table 1, and the outcomes of the Mann–Whitney test are summarized in Table 2. The interclass correlation coefficient between the two examiners in neutral rotation was 0.917 ( $P < 0.01$ ), in internal rotation, it was 0.924 ( $P < 0.01$ ), and in external rotation, it was 0.948 ( $P < 0.01$ ). The Mann–Whitney test between the control group and the study group in neutral rotation was 0.907, in internal rotation, it was 0.932, and in external rotation, it was 0.602. The interclass correlation coefficient was highly significant for the two surgeons, demonstrating that the data were reproducible. The neutral, external, and internal grade measurements of patients with glenoid erosion were not significantly different between patients who underwent revision and patients who did not.

## Discussion

The most important finding of the present study is the absence of a significant difference between the CSA values in patients with glenoid erosion following shoulder hemiarthroplasty and patients without glenoid erosion. In addition, the measurements were reproducible, with a good correlation coefficient between the two examiners in neutral rotation, internal rotation, and external rotation. Glenoid erosion, which is one the recognized complications

**Table 2** Mann–Whitney test

Null hypothesis	Sig.	Decision
CSA (sg)/CSA (cg) NR	0.907	Retain the null hypothesis
CSA (sg)/CSA (cg) IR	0.932	Retain the null hypothesis
CSA (sg)/CSA (cg) ER	0.602	Retain the null hypothesis

Asymptotic significances are displayed. The significance is 0.05

CSA critical shoulder angle, Sg study group, Cg control group, NR neutral rotation, IR internal rotation, ER external rotation

after HA, is a source of concern after shoulder hemiarthroplasty [17]. It is a major cause of clinical deterioration at long-term follow-up and final conversion to reverse arthroplasty [18]. A recent study reported a satisfaction rate of 25% after hemiarthroplasty at 17 years follow-up [10]. Glenoid erosion has been described in up to 72% of cases with first generation implants [13]; however, this rate has decreased with more recent designs [11, 12]. However, 42% of patients with failed shoulder hemiarthroplasties had substantial glenoid erosion [19]. According to these findings and despite the improvement of surgical techniques and implant designs, symptomatic glenoid erosion is still a problem. Several recent studies have investigated the role of anatomic factors in the development of shoulder osteoarthritis (OA). Nyffeler et al. described the acromion index as the lateral extension of the acromion [20]. Nyffeler et al. postulated that a short acromion would lead to a predominance of the compressive component of the deltoid with increased loads on joint and increased degenerative wear and OA. Conversely, they reported no significant correlation between a low index and glenohumeral joint OA.

Recently, Moor et al. investigated the role of a new parameter, namely, the critical shoulder angle (CSA) [14]. The CSA was drawn between the tangent to the inferior and the superior poles of the glenoid fossa and the line connecting the inferior apex of the glenoid with the most infero-lateral aspect of the acromion. Moor et al. found that CSA values were significantly smaller in patients with OA than in normal subjects, and concluded that shoulders with CSA values  $<30^\circ$  are likely to be osteoarthritic. Patients with decreased CSA values would have predominance of compressive forces over superiorly directed forces resulting in an overload of the cartilage with further degeneration. Their methodology is reliable, and the assessment of the CSA yielded variability  $\leq 2^\circ$  for malrotations of the scapular position of up to  $20^\circ$  of internal rotation or extension and  $20^\circ$  of external rotation or flexion [14]. Recently, Suter et al. carried out a 3D CT scan study on cadaver scapulae to assess the influence of scapular position on the reproducibility of the CSA [21]. The measured CSA in true AP views was compared with those calculated

with the scapulae in anteversion/retroversion and extension/flexion. In addition, the relationship between the CSA and glenoid size, gender, and side was assessed. Anteversion and retroversion greatly influenced CSA values. Conversely glenoid height, width, height/width ratio, version, and side did not strongly influence CSA values. Finally, good intra- and inter-observer reliability were reported.

The present study is the first to investigate the relationship between CSA and symptomatic glenoid erosion after shoulder hemiarthroplasty. Extrapolating the findings by Moor et al. [14], we hypothesized that our 28 patients who developed symptomatic glenoid erosion after shoulder hemiarthroplasty would have lower CSA values than a control group. The results, however, did not confirm our hypothesis. No statistically significant difference emerged in CSA values between the two groups. Nevertheless, the methodology of CSA measurement was demonstrated to be reproducible with a good interclass correlation coefficient in neutral, internal, and external rotation views. Thus, CSA can be used as a reliable tool in future studies, although its clinical usefulness remains to be elucidated. Even though the hypothesis was found to be not true and contradictory to previous Moor et al. results, these new findings could enhance further research in this subject.

The present investigation has some limitations. First, it is a retrospective comparison of two groups with slight differences in the initial etiologies. However, the uniqueness of the study and the length of the follow-up did not allow us to select perfectly matching populations. In any case, these slight differences were not considered a source of major bias and the CSA measures were carried out according to the initial aetiologies in the two groups as well. From one hand, this reduced the number of patients in the different groups (osteoarthritis, necrosis, and fractures), thus reducing the statistical significance of the outcomes. However, the similar CSA values in the three groups confirmed that the initial aetiology was not a factor affecting the outcomes. Second, the power analysis showed a minimum sample size of 28 patients in both groups to detect a significant difference. Unfortunately, the strict inclusion criteria (only patients with symptomatic glenoid erosion requiring revision surgery) reduced the initial study population. Third, the length of follow-up was different between the two groups. Nonetheless, although the follow-up in the control group was much longer than in the study group, this would not have exerted an appreciable influence on the parameters being evaluated.

Symptomatic glenoid erosion has been related to deteriorating outcomes after shoulder hemiarthroplasty, and is a major cause for late revision. Preventing glenoid erosion would be of a great interest in terms of costs and patients' quality of life. Anatomic studies have demonstrated a

significant association between low critical shoulder angle values and degenerative changes in the glenohumeral joint, postulating the prevalence of compressive forces. In a similar way, we hypothesized a role of decreased critical shoulder angle in the development of glenoid erosion after shoulder hemiarthroplasty. We did not identify a significant difference of CSA values between patients who did develop symptomatic glenoid erosion and those who did not.

#### Compliance with ethical standards

**Conflict of interest** The authors declare that they have no potential conflict of interest.

**Ethical approval** All procedures performed in studies involving human participants were in accordance with the ethical standards of the institutional and/or national research committee and with the 1964 Helsinki declaration and its later amendments or comparable ethical standards.

#### References

- Neer CS II (1970) Displaced proximal humeral fractures. II. Treatment of three-part and four-part displacement. *J Bone Jt Surg Am* 52(6):1090–1103
- Wirth MA, Tapscott RS, Southworth C, Rockwood CA Jr (2006) Treatment of glenohumeral arthritis with a hemiarthroplasty: a minimum five-year follow-up outcome study. *J Bone Jt Surg Am* 88(5):964–973
- Smith RG, Sperling JW, Cofield RH, Hattrup SJ, Schleck CD (2008) Shoulder hemiarthroplasty for steroid-associated osteonecrosis. *J Shoulder Elbow Surg* 17(5):685–688
- Sperling JW, Cofield RH, Schleck CD, Harmsen WS (2007) Total shoulder arthroplasty versus hemiarthroplasty for rheumatoid arthritis of the shoulder: results of 303 consecutive cases. *J Shoulder Elbow Surg* 16(6):683–690
- Williams GR Jr, Rockwood CA Jr (1996) Hemiarthroplasty in rotator cuff-deficient shoulders. *J Shoulder Elbow Surg* 5(5):362–367
- Pape G, Zeifang F, Bruckner T, Raiss P, Rickert M, Loew M (2010) Humeral surface replacement for the sequelae of fractures of the proximal humerus. *J Bone Jt Surg Br* 92(10):1403–1409
- Parsons IMT, Millett PJ, Warner JJ (2004) Glenoid wear after shoulder hemiarthroplasty: quantitative radiographic analysis. *Clin Orthop Relat Res* 421:120–125
- Bryant D, Litchfield R, Sandow M, Gartsman GM, Guyatt G, Kirkley A (2005) A comparison of pain, strength, range of motion, and functional outcomes after hemiarthroplasty and total shoulder arthroplasty in patients with osteoarthritis of the shoulder. A systematic review and meta-analysis. *J Bone Jt Surg Am* 87(9):1947–1956
- Haines JF, Trail IA, Nuttall D, Birch A, Barrow A (2006) The results of arthroplasty in osteoarthritis of the shoulder. *J Bone Jt Surg Br* 88(4):496–501
- Levine WN, Fischer CR, Nguyen D, Flatow EL, Ahmad CS, Bigliani LU (2012) Long-term follow-up of shoulder hemiarthroplasty for glenohumeral osteoarthritis. *J Bone Jt Surg Am* 94(22):e164
- Edwards TB, Kadakia NR, Boulahia A, Kempf JF, Boileau P, Nemoz C, Walch G (2003) A comparison of hemiarthroplasty and total shoulder arthroplasty in the treatment of primary glenohumeral osteoarthritis: results of a multicenter study. *J Shoulder Elbow Surg* 12(3):207–213
- Gadea F, Alami G, Pape G, Boileau P, Favard L (2012) Shoulder hemiarthroplasty: outcomes and long-term survival analysis according to etiology. *Orthop Traumatol Surg Res* 98(6):659–665
- Sperling JW, Cofield RH, Rowland CM (2004) Minimum fifteen-year follow-up of Neer hemiarthroplasty and total shoulder arthroplasty in patients aged fifty years or younger. *J Shoulder Elbow Surg* 13(6):604–613
- Moor BK, Bouaicha S, Rothenfluh DA, Sukthankar A, Gerber C (2013) Is there an association between the individual anatomy of the scapula and the development of rotator cuff tears or osteoarthritis of the glenohumeral joint?: a radiological study of the critical shoulder angle. *Bone Jt J* 95-B(7):935–941
- Moor BK, Wieser K, Slankamenac K, Gerber C, Bouaicha S (2014) Relationship of individual scapular anatomy and degenerative rotator cuff tears. *J Shoulder Elbow Surg* 23(4):536–541
- Rosset A, Spadola L, Ratib O (2004) OsiriX: an open-source software for navigating in multidimensional DICOM images. *J Digit Imaging* 17(3):205–216
- Jacxsens M, Walz T, Durchholz H, Muller AM, Flury M, Schwyzer HK, Audige L (2017) Towards standardised definitions of shoulder arthroplasty complications: a systematic review of terms and definitions. *Arch Orthop Trauma Surg* 137(3):347–355
- Holschen M, Franetzki B, Witt KA, Liem D, Steinbeck J (2017) Conversions from anatomic shoulder replacements to reverse total shoulder arthroplasty: do the indications for initial surgery influence the clinical outcome after revision surgery? *Arch Orthop Trauma Surg* 137(2):167–172
- Hasan SS, Leith JM, Campbell B, Kapil R, Smith KL, Matsen FA 3rd (2002) Characteristics of unsatisfactory shoulder arthroplasties. *J Shoulder Elbow Surg* 11(5):431–441
- Nyffeler RW, Werner CM, Sukthankar A, Schmid MR, Gerber C (2006) Association of a large lateral extension of the acromion with rotator cuff tears. *J Bone Joint Surg Am* 88(4):800–805
- Suter T, Gerber Popp A, Zhang Y, Zhang C, Tashjian RZ, Henninger HB (2015) The influence of radiographic viewing perspective and demographics on the critical shoulder angle. *J Shoulder Elbow Surg* 24:e149–e158